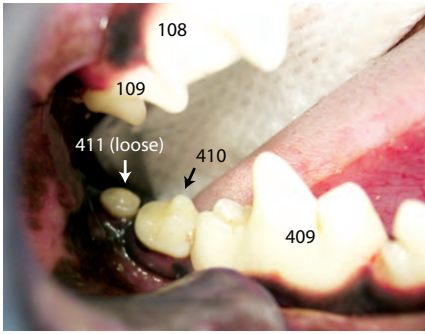
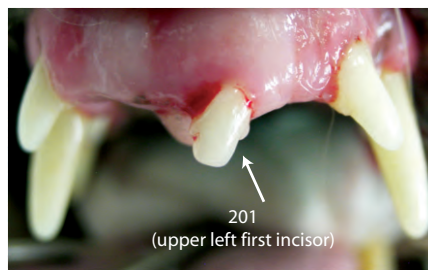
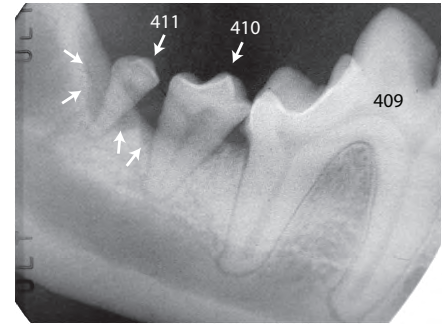


Find the Problems Hidden Under the Gums - Canine



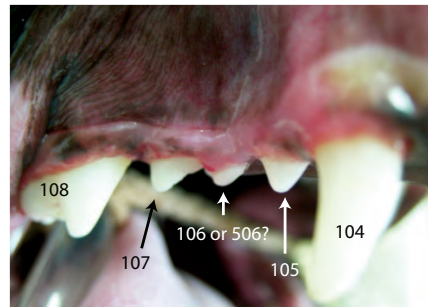
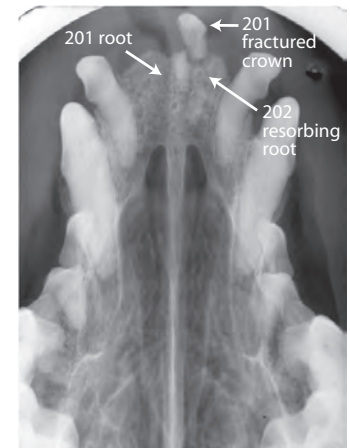
Bone Loss (Periodontitis)

- 3 year old M Min Poodle
- Photo: 410, 411: normal gum level, no calculus, minimal gingivitis
- Dental X-ray: 410, 411 show severe bone loss; we see that 410 roots convergent, not divergent, so we can use appropriate extraction technique
- TX: 410 & 411 extracted; this helps protect 409, an important tooth we want to keep!



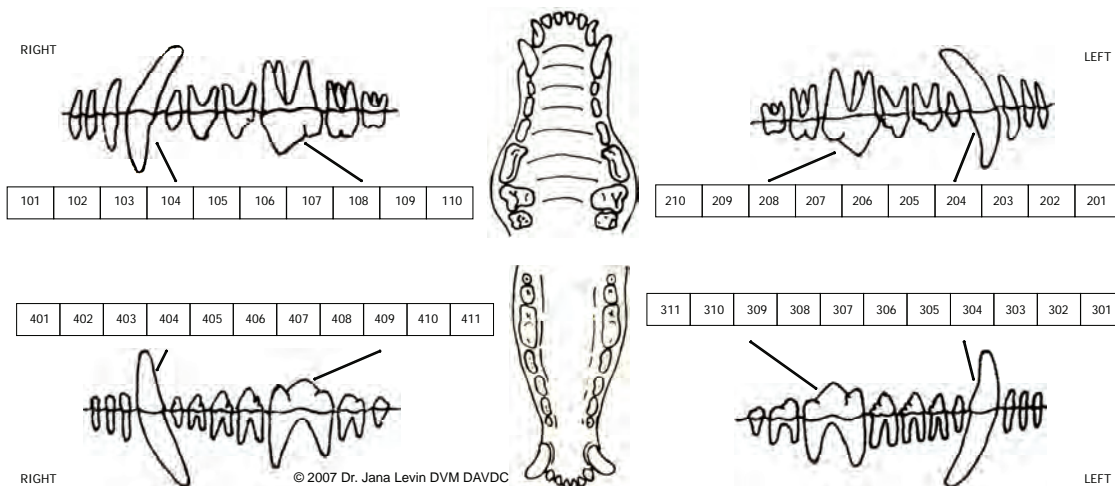
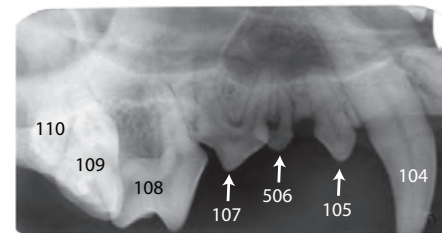
Tooth Fractured Under Gum

- 8 year old MN Westie, just adopted
- Photo: 3 upper incisors appear to be missing
- Dental X-ray: 201 fractured under gumline & crown displaced, root present; 202 root resorbing
- TX: retrieval of 201 crown & root; resorbing root of 202 intentionally left

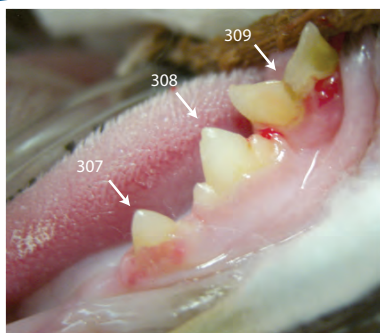


Retained Deciduous Tooth

- 2 year old FS CHI X
- Photo: Are we looking at 4 adult premolars or 3 adult teeth and 1 deciduous (baby) tooth?
- Dental X-ray: 106 missing; retained 506 (baby 2nd premolar) is crowding 107 & increasing risk of bone loss
- TX: extract 506
- Note: baby/deciduous teeth are numbered as upper right = 500s, upper left = 600s, lower left = 700s, lower right = 800s

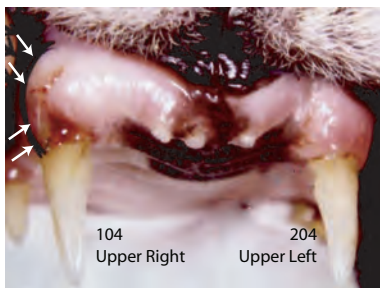
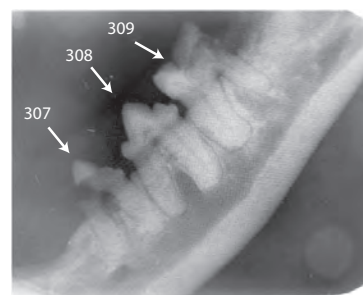


Find the Problems Hidden Under the Gums - Feline



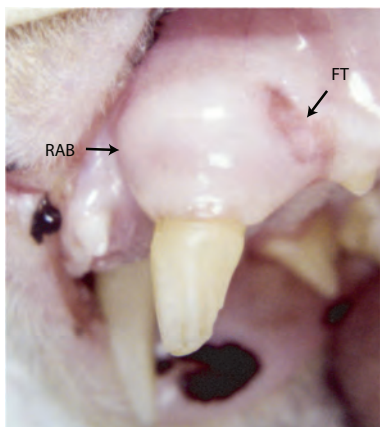
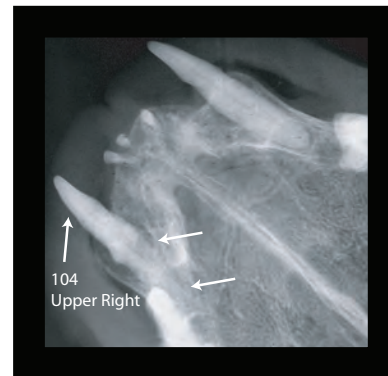
Resorptive Lesions

- 6 year old FS DSH calico
- Photo: 307: inflamed gum growing up onto tooth; 309: open resorptive lesion
- Dental X-ray: extensive 307 crown destruction; note full roots present 307 & 309; we need to know this to treat appropriately
- TX: 309: extracted completely; 307: crown amputated, coronal third roots atomized; 308: no Tx at this time



"Alveolar Bulge" (Reactive Alveolar Bone)

- 10 year old MN DSH
- Photo: Gum above 104 bulges out (arrows); note crown is intact
- Dental X-ray: Root of 104 shows advanced resorption (white arrows)
- TX: Extract 104 (& incisors); entire tooth was retrieved; some resorbing teeth have become "one with the jaw" and are best treated by crown amputation/atomization
- The "Alveolar Bulge" can be caused by resorption &/or root abscess &/or periodontitis



Fractured Canine

- 11 year old MN DSH
- Photo: Open fracture of 204 (upper left canine); note reactive alveolar bone (RAB) and fistulous tract (FT)
- Dental X-ray: Root of 204 large abscess (arrows) with associated resorption; this is a 2-3 year old tooth in an 11-year-old patient
- TX: 204 extracted

